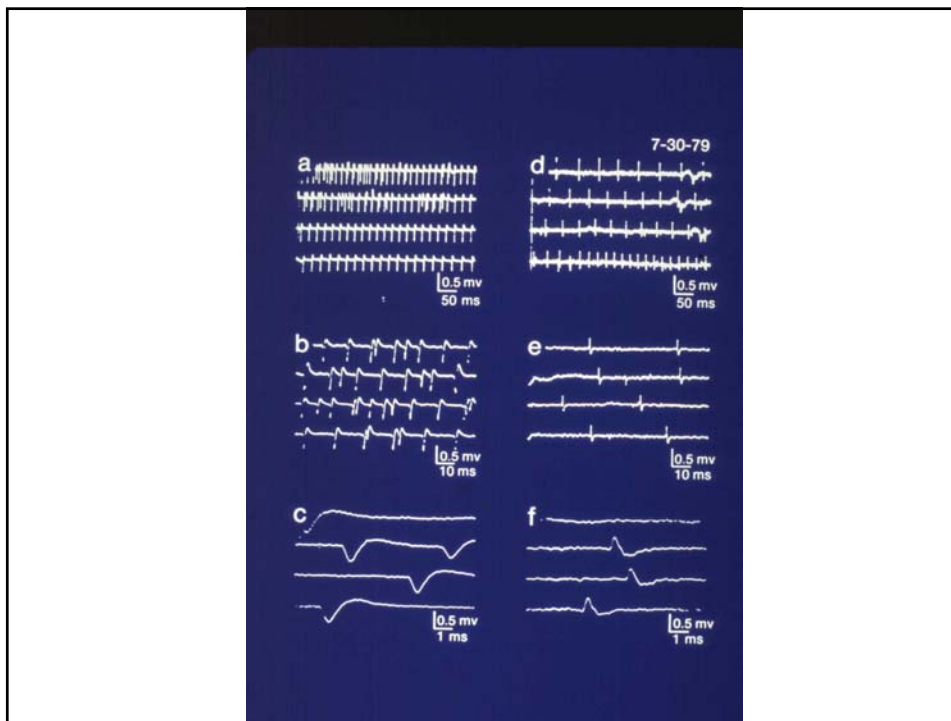
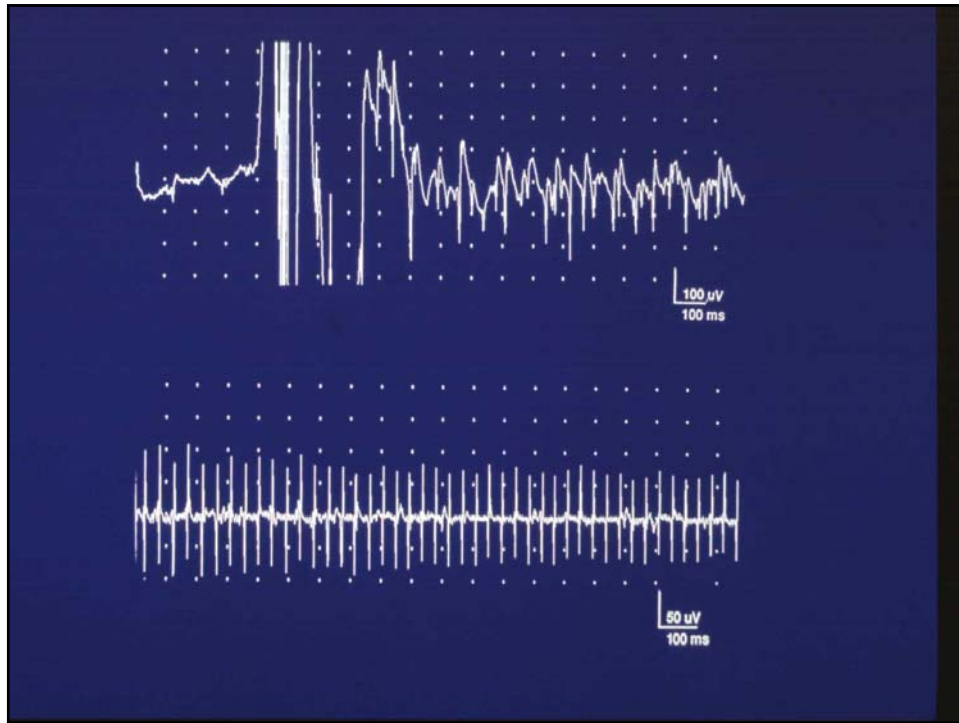


## EMG FINDINGS

EMG \ LESION	NEUROGENIC LESION		MYOGENIC LESION			
	NORMAL	Lower Motor	Upper Motor	Myopathy	Myotonia	Polymyositis
1 Insertional Activity	Normal 	Increased 	Normal 	Normal 	Myotonic Discharge 	Increased 
2 Spontaneous Activity	—	Fibrillation  Positive Wave 	—	—	—	Fibrillation  Positive Wave 
3 Motor Unit Potential	0.5-1.0 mv  5-10msec	Large Unit  Limited Recruitment 	Normal 	Small Unit  Early Recruitment 	Myotonic Discharge 	Small Unit  Early Recruitment 
4 Interference Pattern	Full 	Reduced  Fast Firing Rate 	Reduced  Slow Firing Rate 	Full  Low Amplitude 	Full  Low Amplitude 	Full  Low Amplitude 





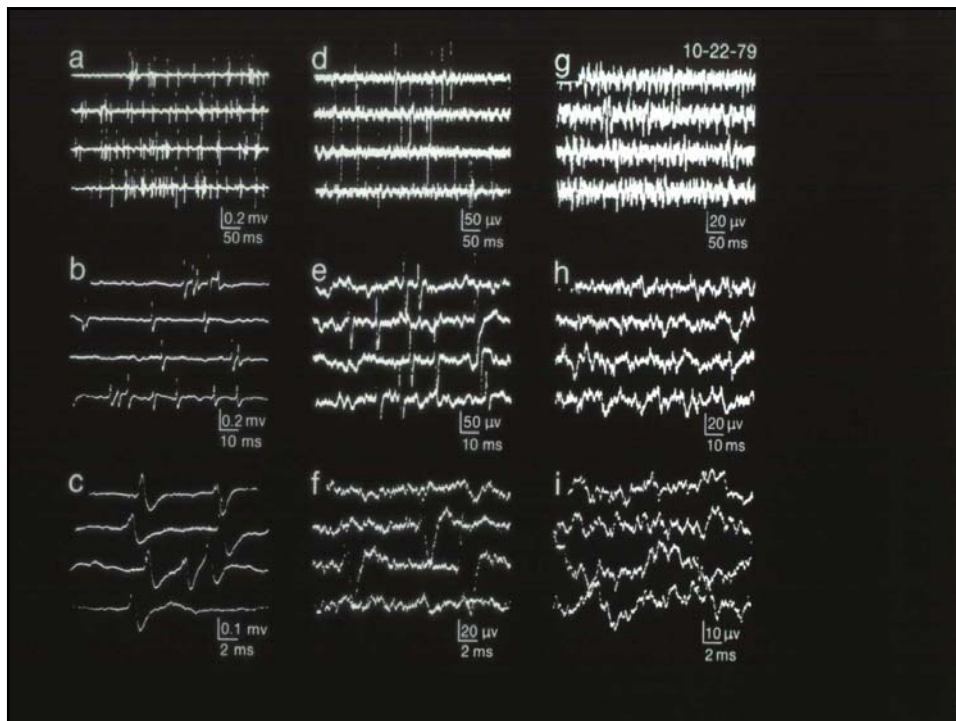
## DISORDERS WITH MYOTONIC DISCHARGES

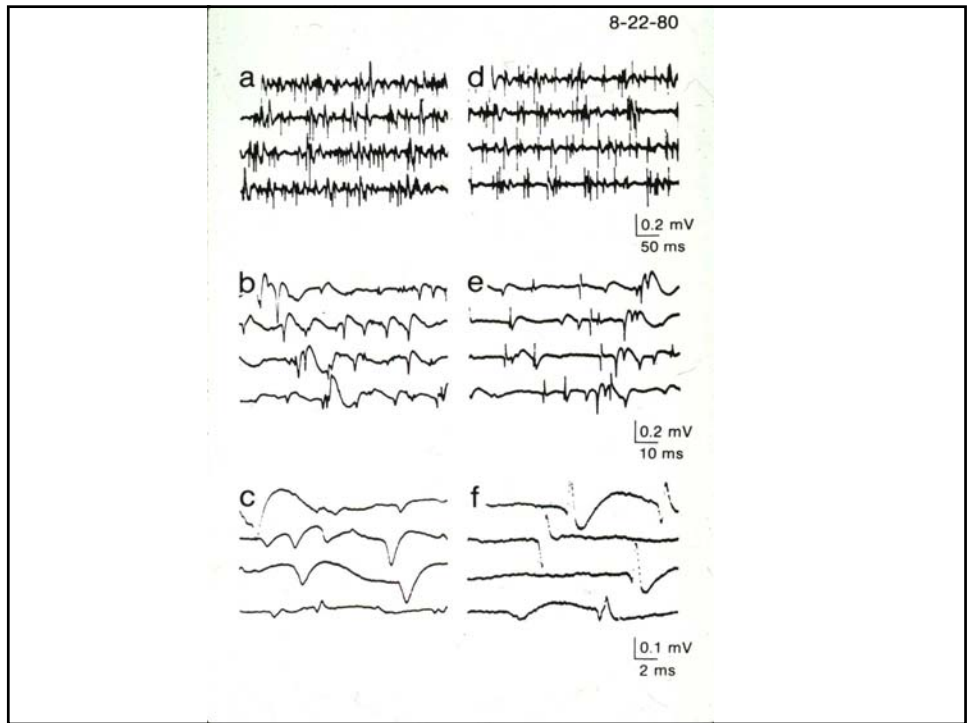
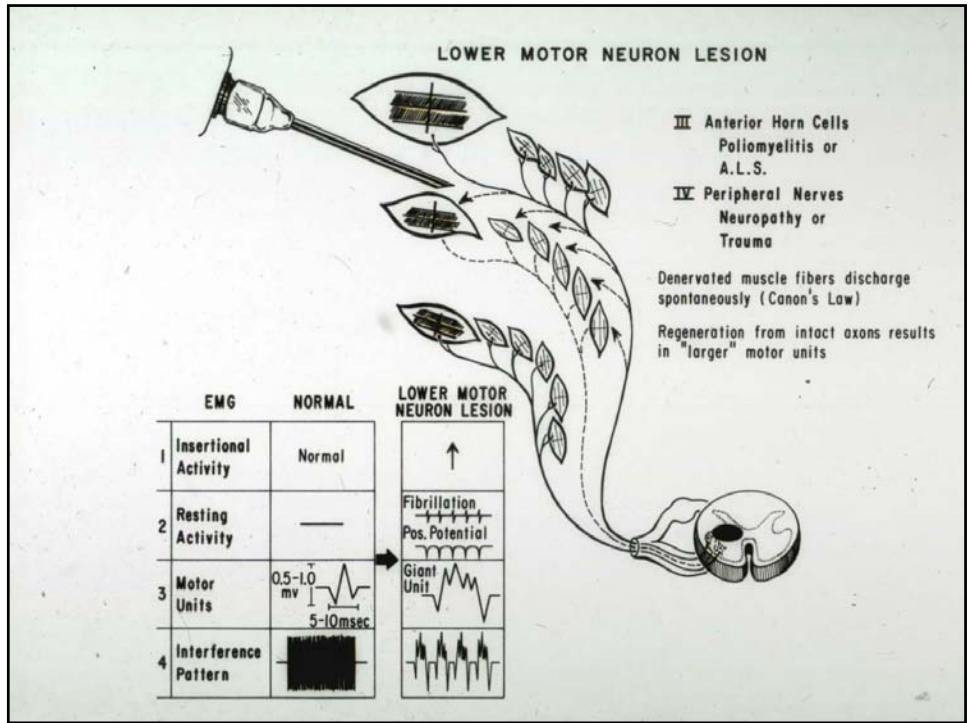
*With Clinical Myotonia*

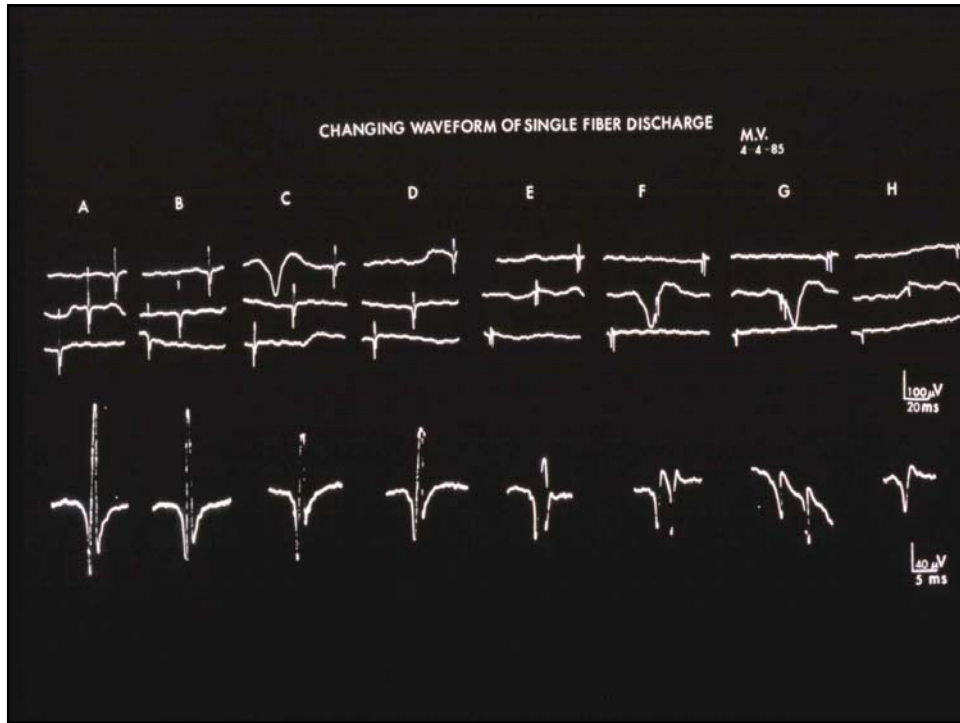
Myotonia Dystrophica  
Myotonia Congenita  
Paramyotonia Congenita  
Hyperkalemic Periodic Paralysis  
Proximal Myotonic Myopathy

*Without Clinical Myotonia*

Myositis  
Acid Maltase Deficiency  
Cytoplasmic Body Myopathy  
Hyperthyroidism  
Hypothyroidism  
Familial Granulovacuolar Lobular Myopathy  
Malignant Hyperpyrexia  
Multicentric Reticulohistiocytosis  
Myopathies induced by:  
Glycyrrhizin  
Hypocholesterolemic agent  
Disagzocholesterol  
Colchicine

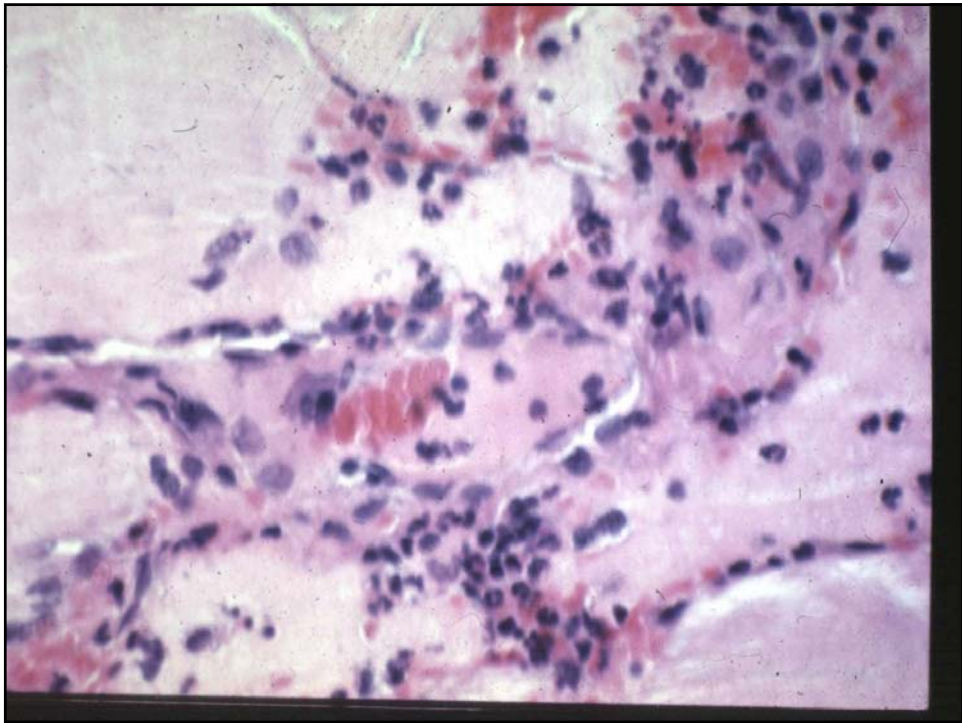
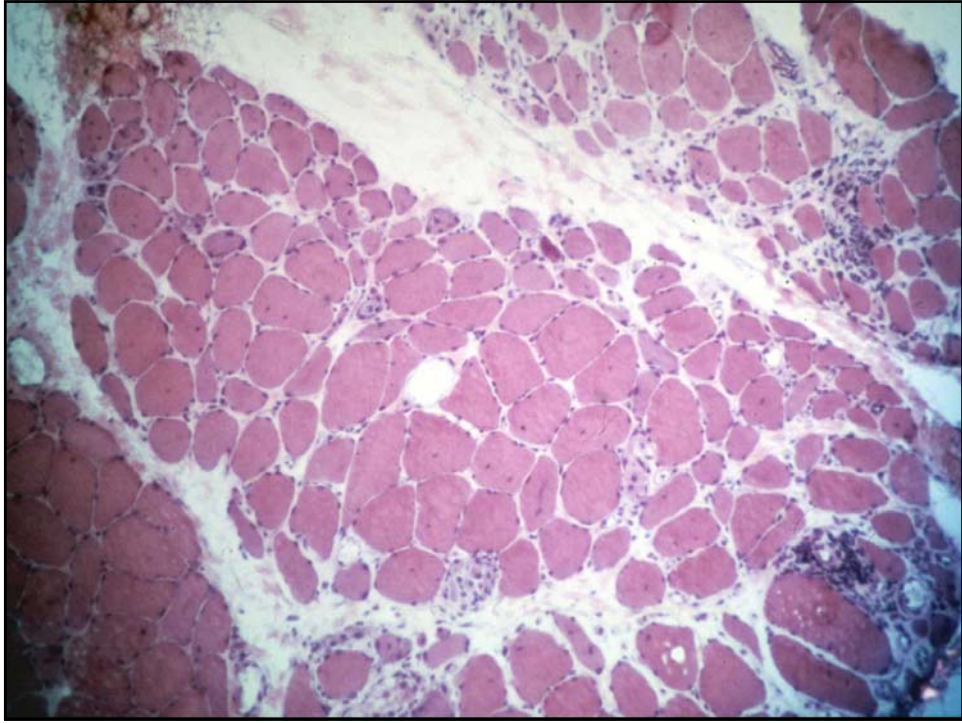




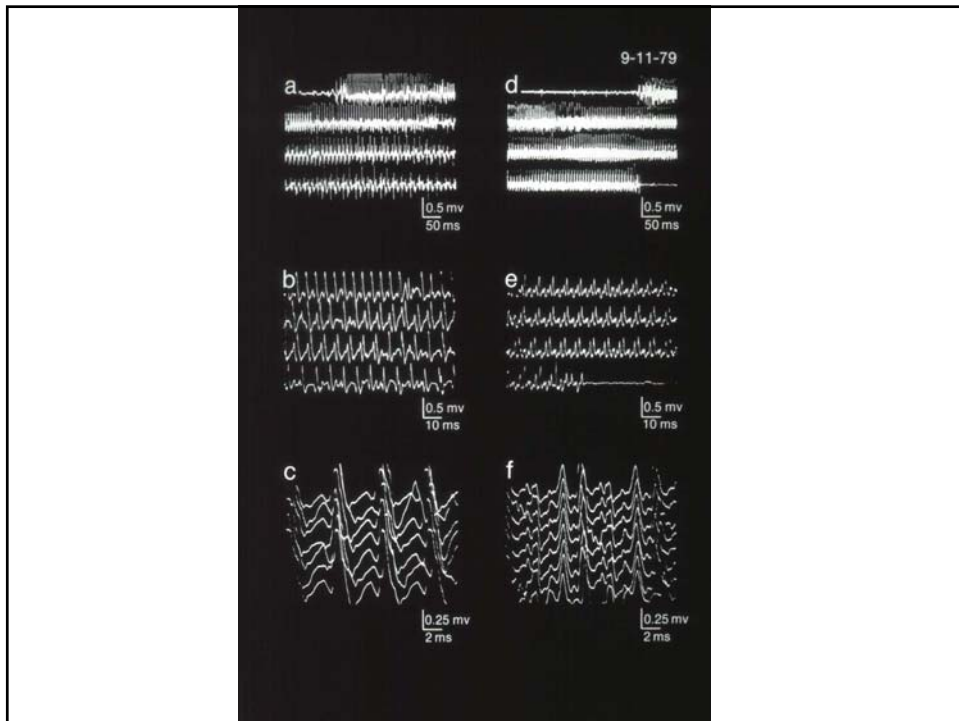
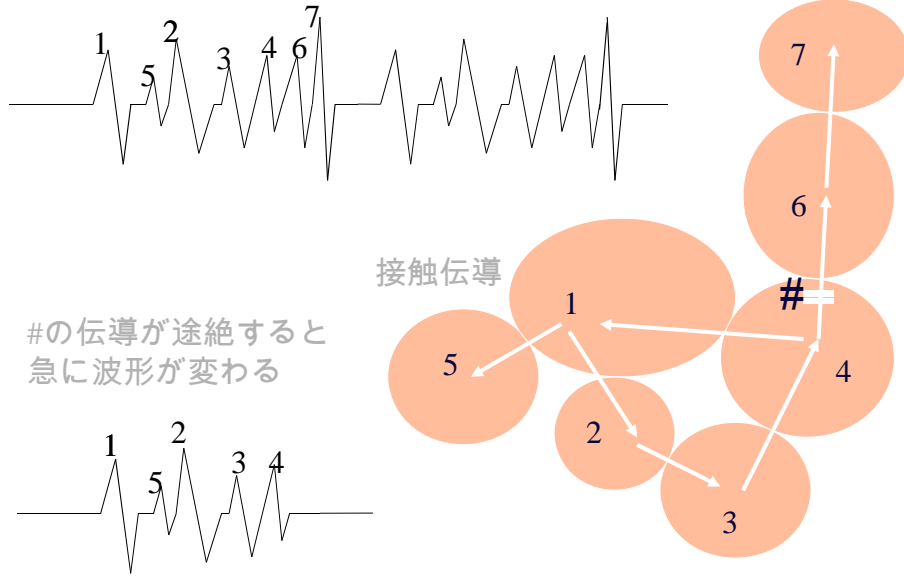


**EMG FINDINGS**

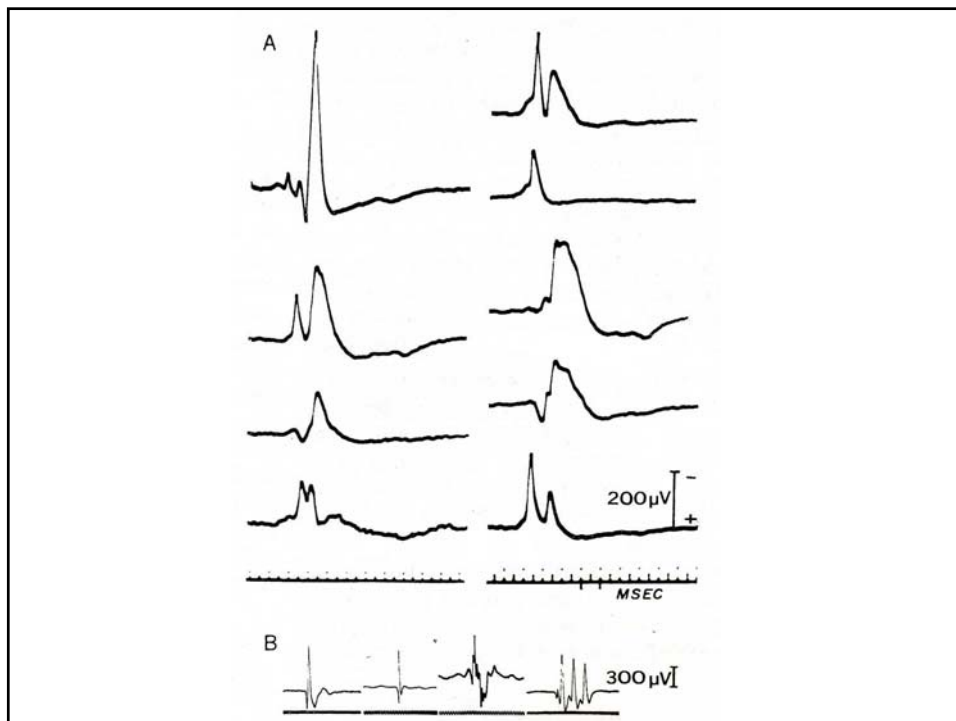
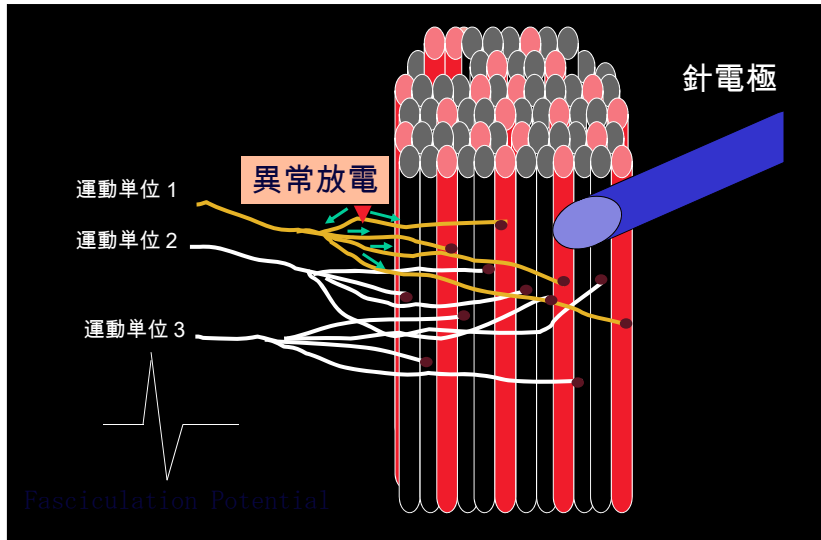
EMG \ LESION	NORMAL	NEUROGENIC LESION		MYOGENIC LESION		
		Lower Motor	Upper Motor	Myopathy	Myotonia	Polymyositis
1 Insertional Activity	Normal 	Increased 	Normal 	Normal 	Myotonic Discharge 	Increased 
2 Spontaneous Activity	—	Fibrillation  Positive Wave 	—	—	—	Fibrillation  Positive Wave 
3 Motor Unit Potential	0.5-1.0 mv  5-10 msec	Large Unit  Limited Recruitment	Normal 	Small Unit  Early Recruitment	Myotonic Discharge 	Small Unit  Early Recruitment
4 Interference Pattern	Full 	Reduced  Fast Firing Rate	Reduced  Slow Firing Rate	Full  Low Amplitude	Full  Low Amplitude	Full  Low Amplitude



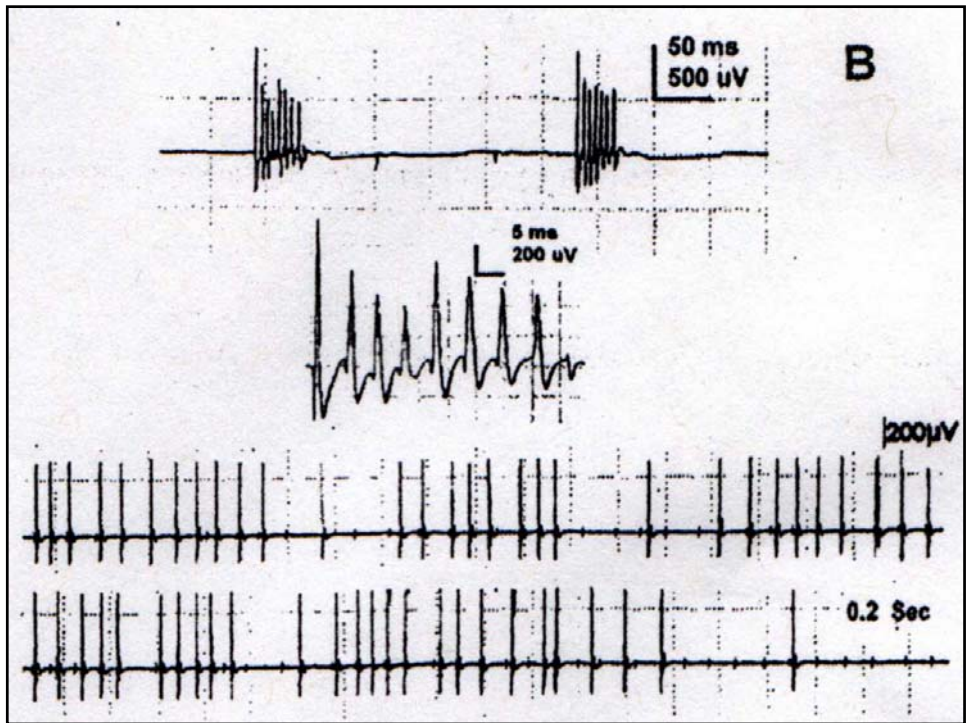
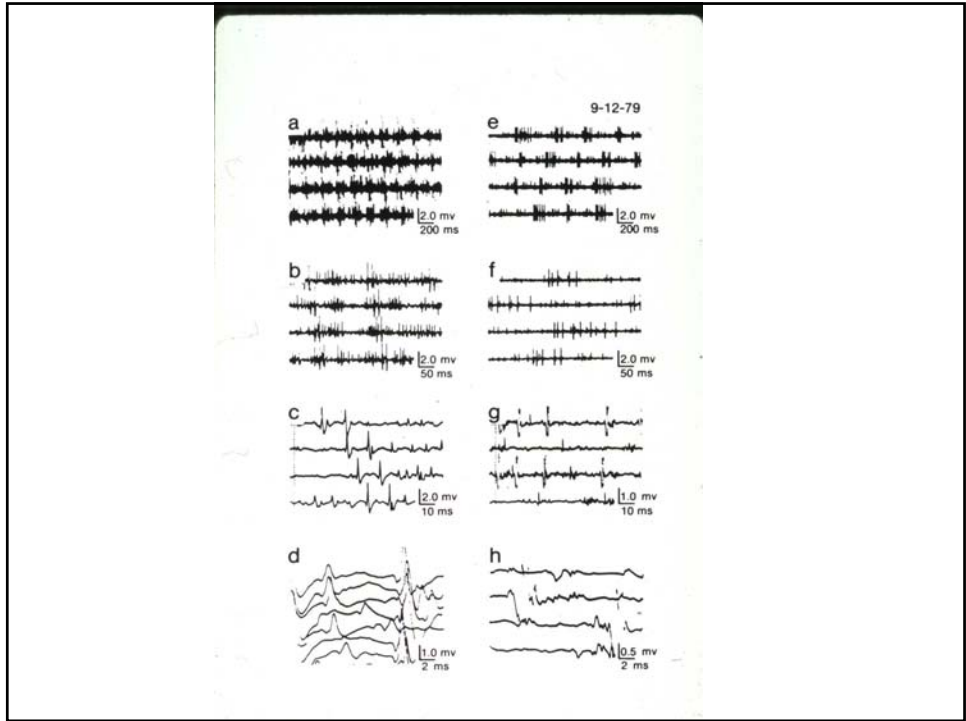
# 複合反復放電のメカニズム

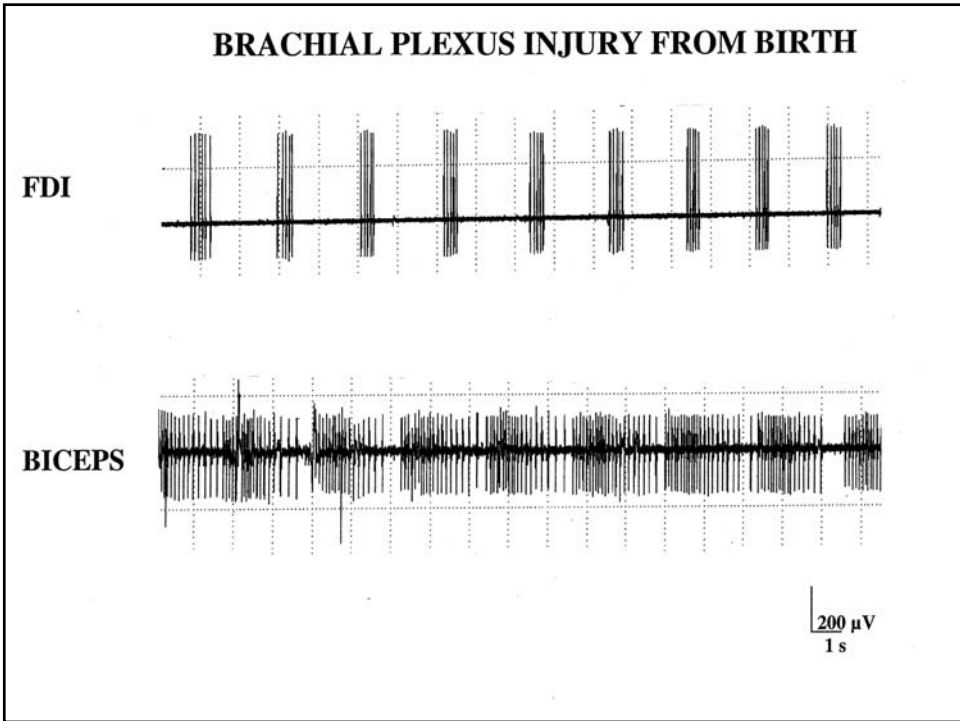
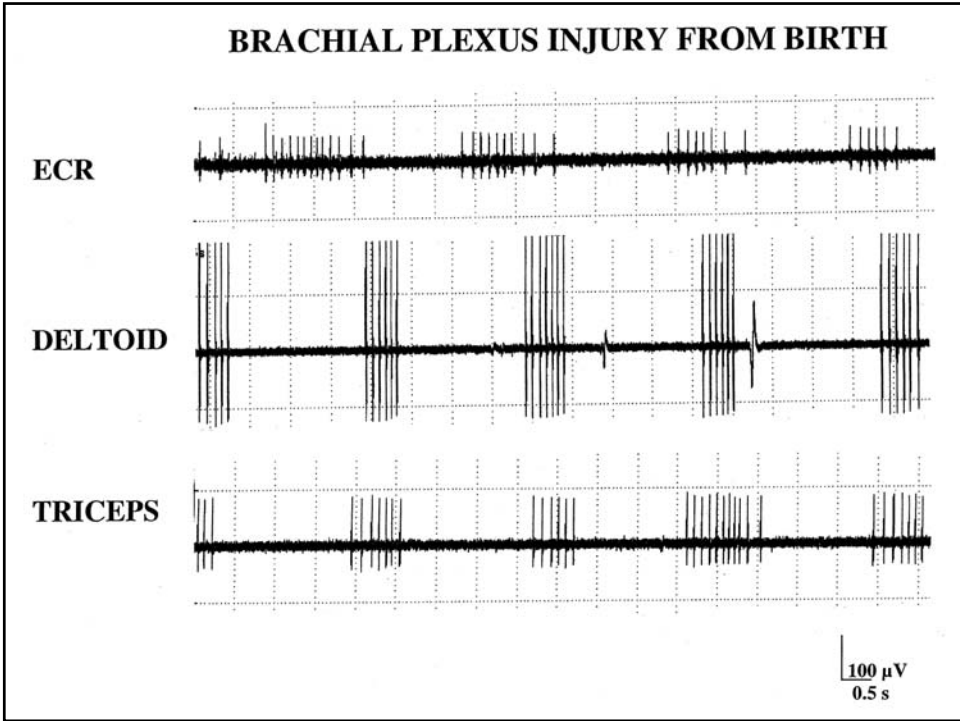


# 運動単位が関連する自発放電









## COMMON TYPES OF SPONTANEOUS DISCHARGES

### 1) *Fibrillation Potentials and Positive Sharp Waves*

Neuropathic Condition  
Muscular Dystrophy  
Myositis

### 2) *Complex Repetitive Discharges*

Motor Neuron Disease  
Radiculopathy  
Chronic Polyneuropathy  
Polymyositis  
Muscular Dystrophy  
Myxedema  
Schwarz-Jampel Syndrome

### 3) *Fasciculation Potentials*

Motor Neuron Disease  
Radiculopathy  
Entrapment Neuropathy  
Muscular Pain – Fasciculation Syndrome  
Healthy Subjects

### 4) *Myokymic Discharges*

Guillain-Barré Syndrome  
Radiation Plexopathy  
Spinal Stenosis  
Nerve Root Compression  
Bell's Palsy  
Multiple Sclerosis  
Syringobulbia

1) *Muscle Fiber*

Insertional Positive Waves  
Myotonic Discharge  
Fibrillation Potential  
Positive Sharp Waves  
Complex Repetitive Discharge  
End-plate Noise  
End-plate Spikes

2) *Lower Motor Neuron*

Fasciculation Potential  
Myokymic Discharge  
Neuromyotonic Discharge  
Cramp Discharges  
Hemifacial Spasm  
Hemimasticatory Spasm

3) *Upper Motor Neuron*

Stiffman Syndrome  
Involuntary Movement